

Graft-versus-host Disease of the Skin, Hair, and Nails

Alina Markova, MD
Dermatologist

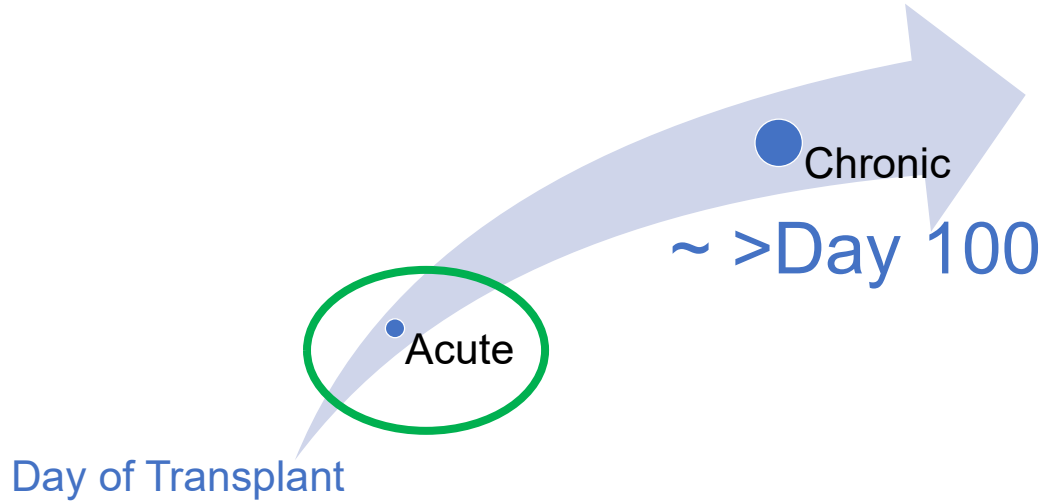
1

GVHD of the Skin, Hair, and Nails: Learning Objectives

1. Understand the various ways chronic GVHD can affect the skin, hair and nails
2. Review the timeline of manifestations of cGVHD on the skin, hair and nails
3. Describe how cutaneous GVHD of the skin, hair, and nails can affect activities of daily living
4. Summarize pharmacological and non-pharmacological therapies that can help patients who have cutaneous GVHD

2

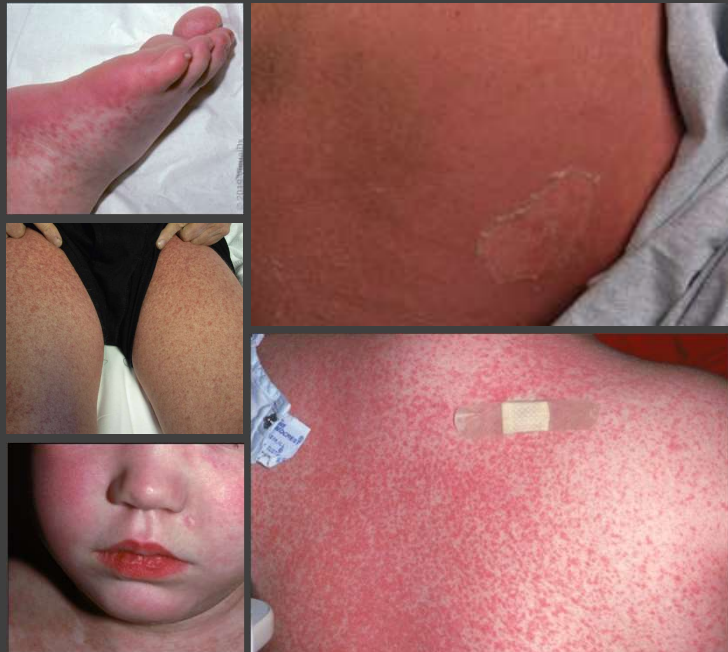There are 2 Presentations of Skin GVHD



3

Acute GVHD of the skin

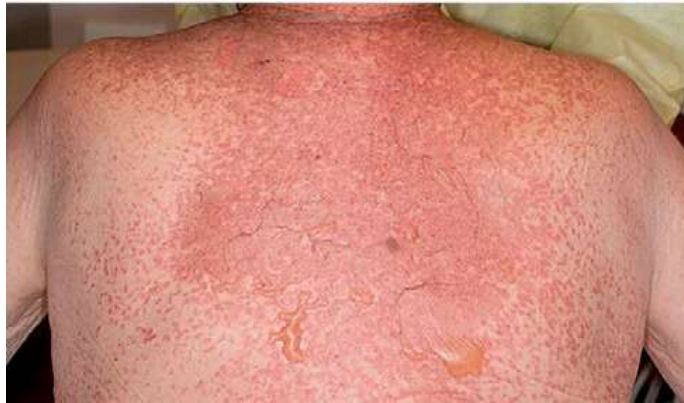- ~First 100 days
- Pink, flat and raised areas
- May be itchy



Visualdx.com, Lacouture, ME. 2013.

4

Rarely, acute
GVHD of the skin
may blister



J Am Acad Dermatol 2012;66:515.e1-18

5

Severity of acute GVHD of the skin is determined by the % of involved skin

Stage	Skin (% body surface area of active areas only)
0	0
1	<25
2	25-50
3	>50
4	>50% blister formation and peeling >5% BSA

6

Acute GVHD of the Skin: Topical approach to therapy


Topical corticosteroids Topical calcineurin inhibitors

NBUVB phototherapy



7

Topicals come in different vehicles



Contain alcohol!

No alcohol!
(water/oil based)

8

Topical therapies for acute GVHD of the skin

Localized

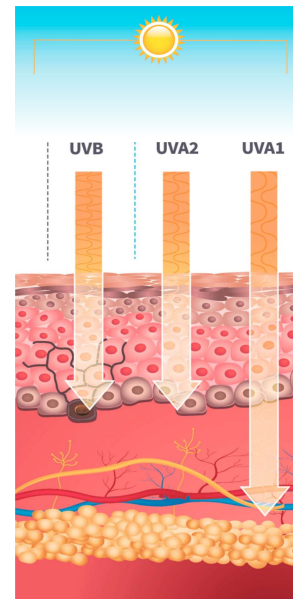
- **Topical steroids twice daily**
- **Topical calcineurin inhibitors twice daily**

Widespread

- **Systemic therapy as per BMT**
- **Narrowband ultraviolet B phototherapy (off-label)**

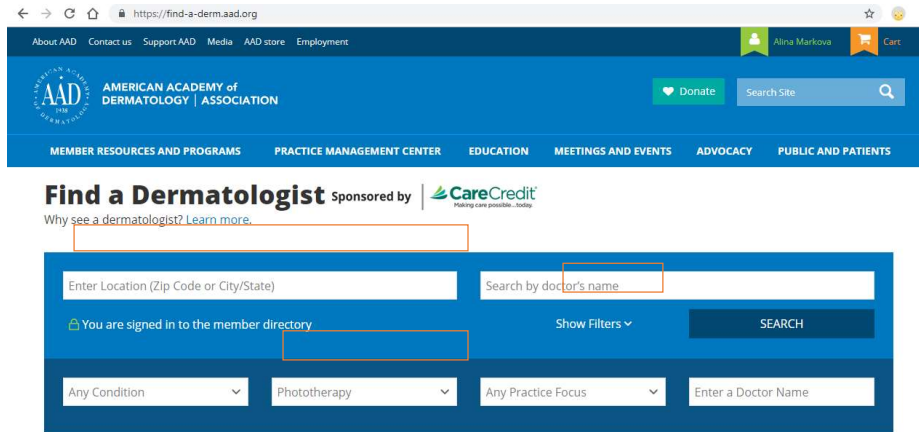
9

How does phototherapy work?



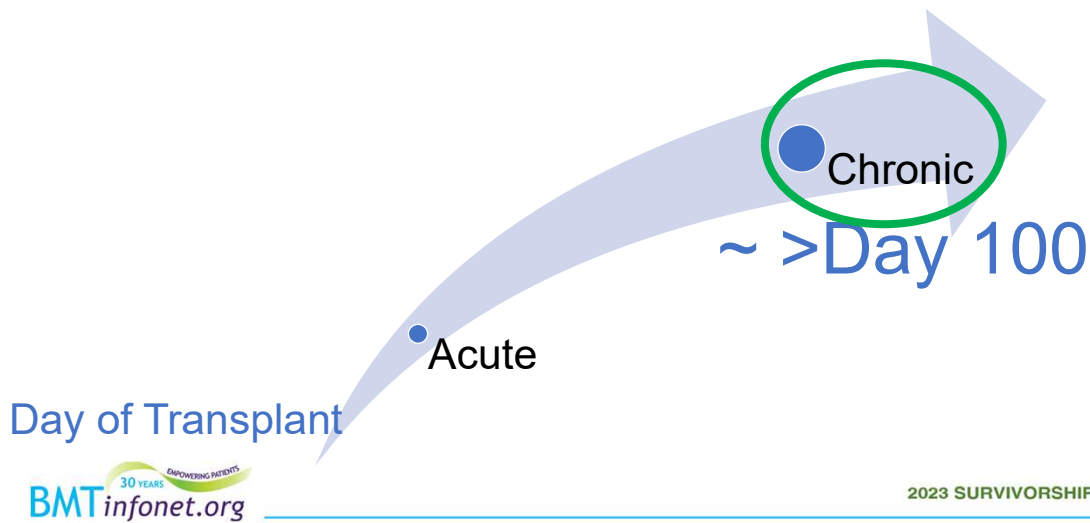
10

Find a Phototherapy Center at aad.org/fad



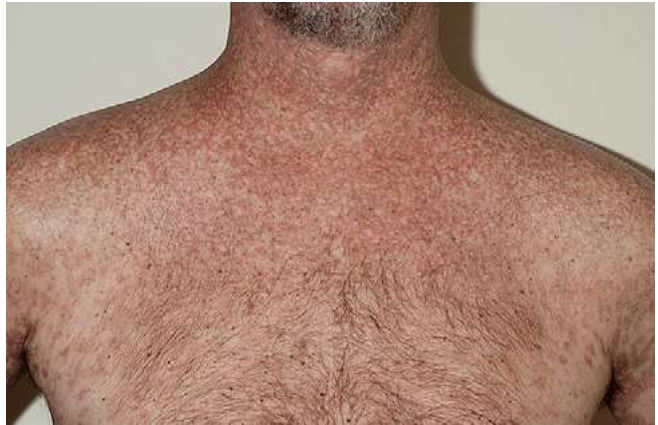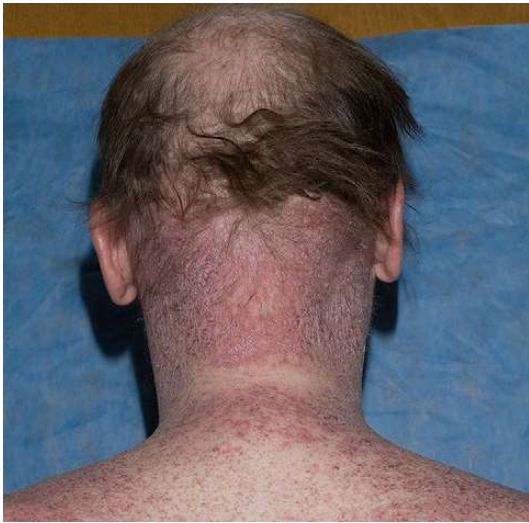11

There are 2 Presentations of Skin GVHD



12

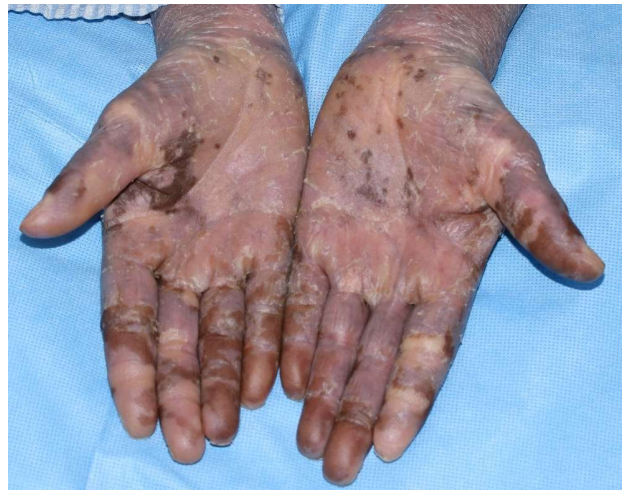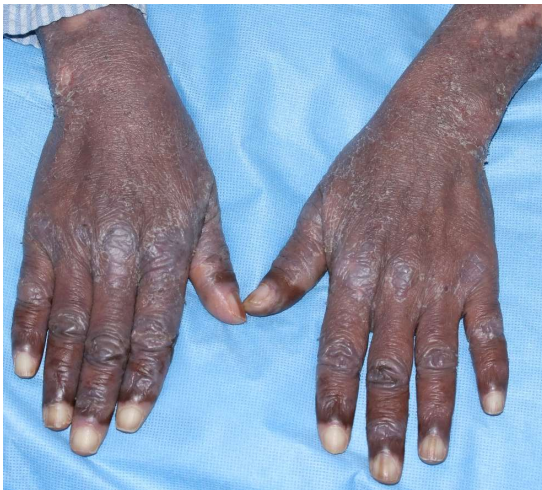Non-scarring (non-sclerotic) lichenoid chronic GVHD



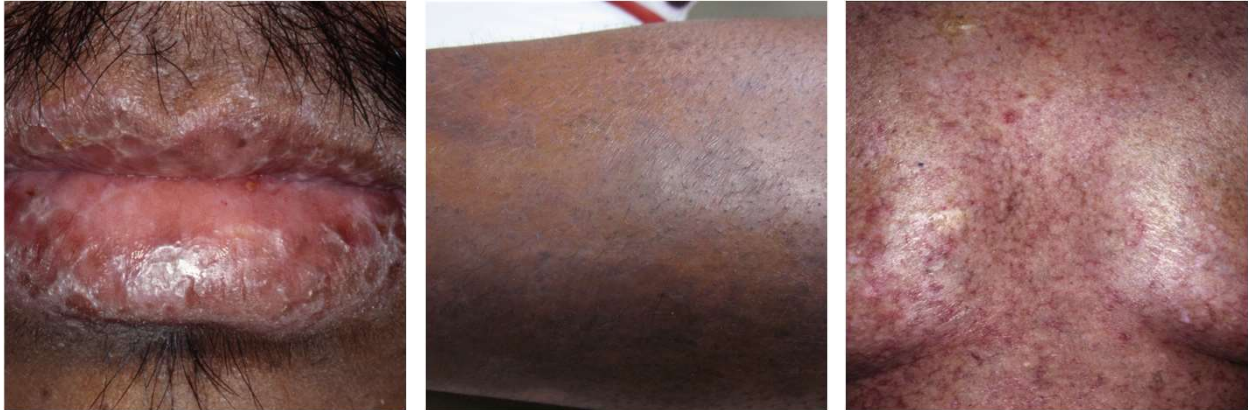J Am Acad Dermatol 2012;66:515.e1-18

13

Lichenoid chronic GVHD may be extensive



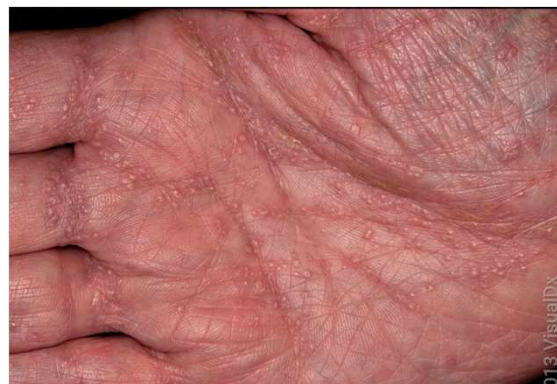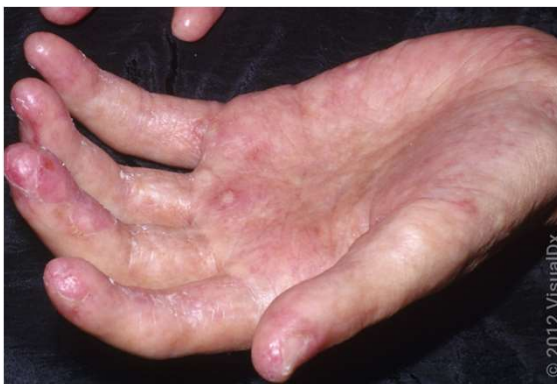14



Chronic GVHD of the Skin: Lichen Planus-like cGVHD

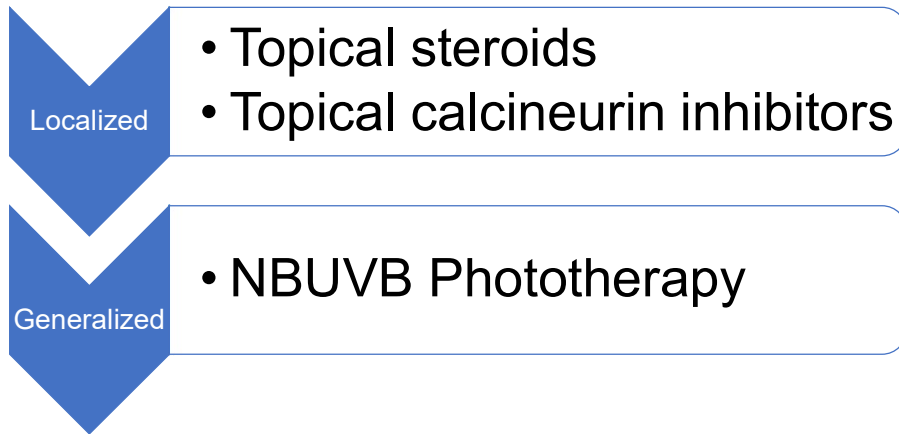
15

Chronic GVHD of the Skin: Lichen planus-like GVHD

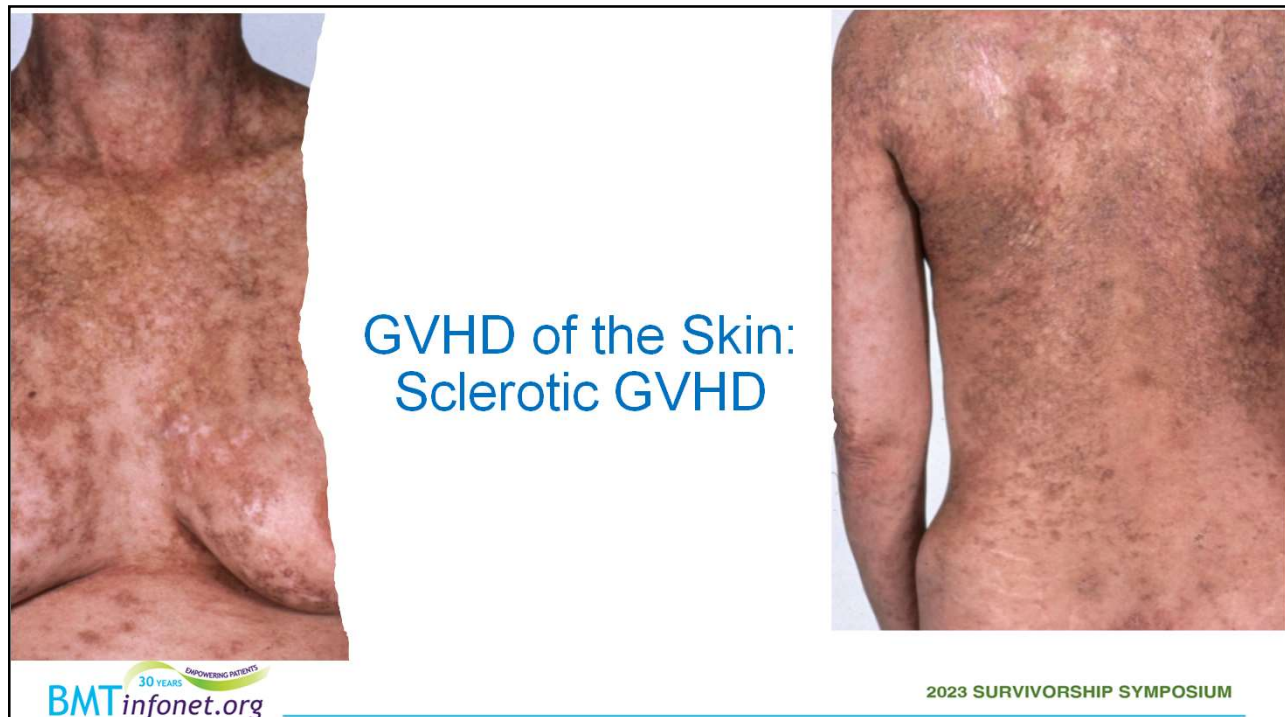

16

Topical therapies for chronic non-scarring skin GVHD



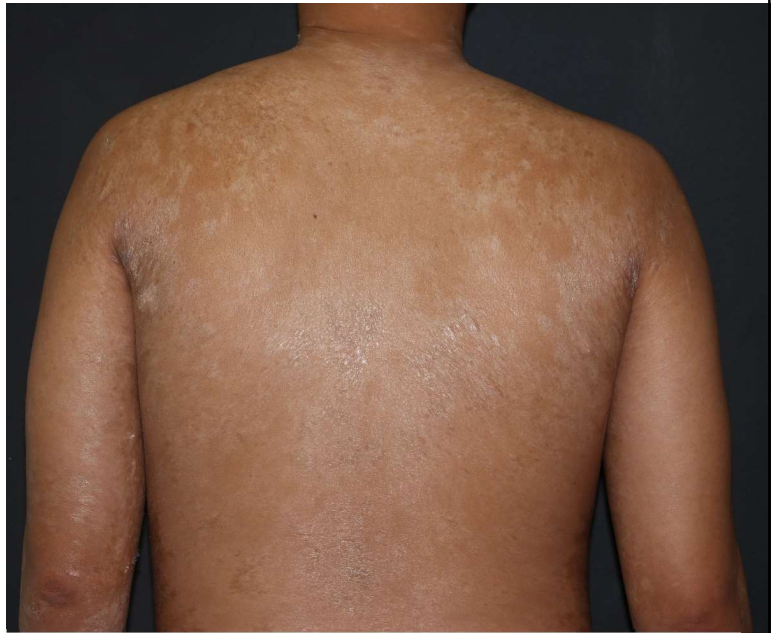17



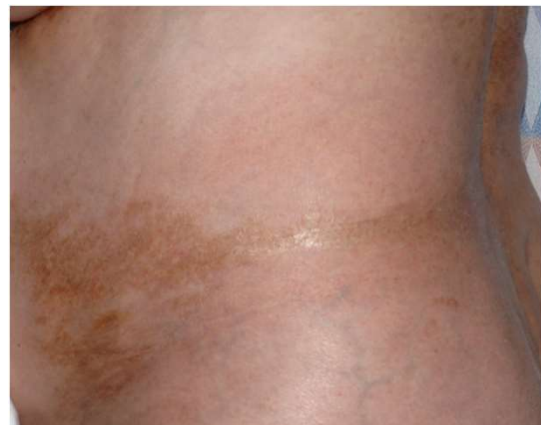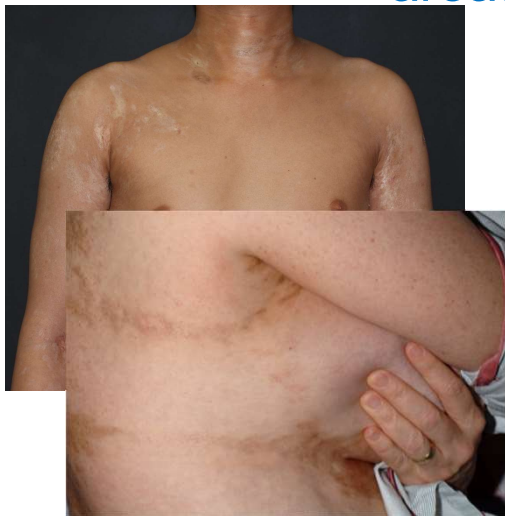GVHD of the Skin: Sclerotic GVHD

18

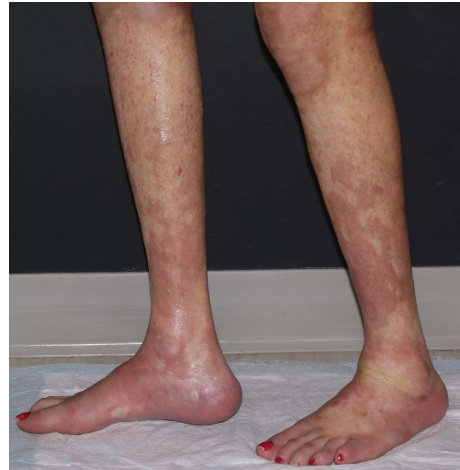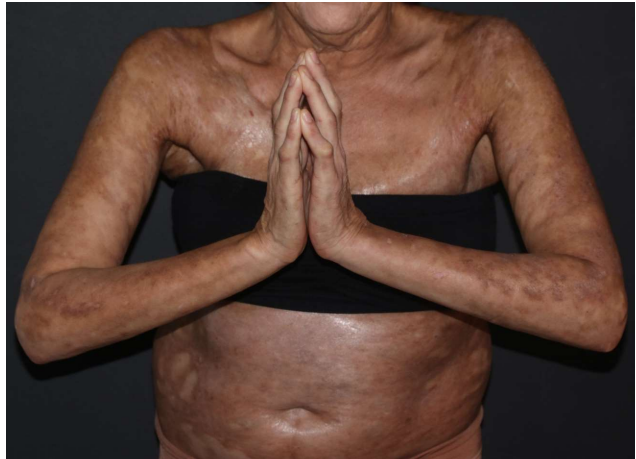SCLEROTIC GVHD



SCLEROTIC GVHD may appear in areas of prior trauma

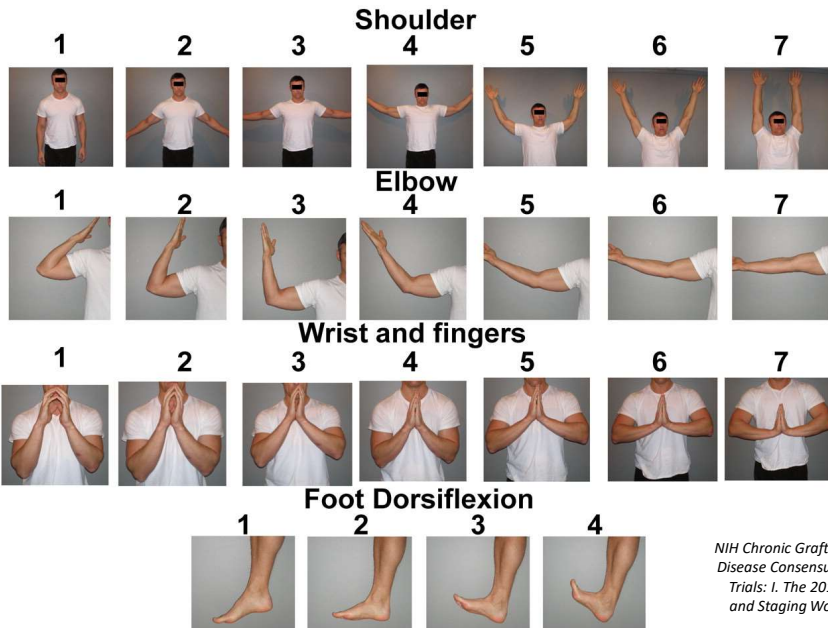


Sclerotic chronic GVHD may lead to reduced range of motion



21

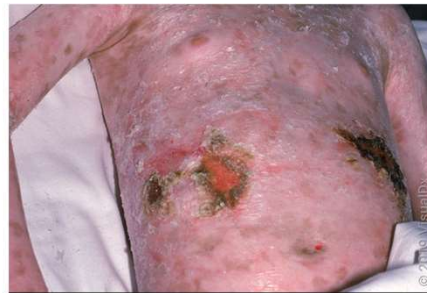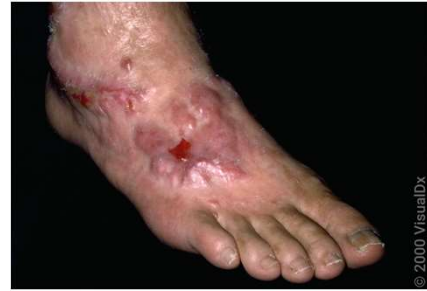Photographic Range of Motion (P-ROM)



NIH Chronic Graft-versus-Host
Disease Consensus for Clinical
Trials: 1. The 2014 Diagnosis
and Staging Working Group
Report

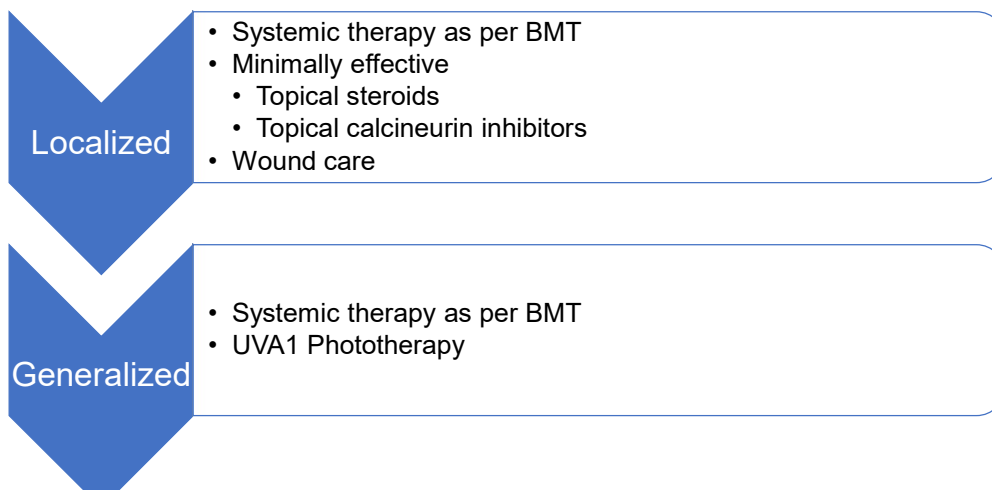
22

Wounds may develop within sclerotic GVHD

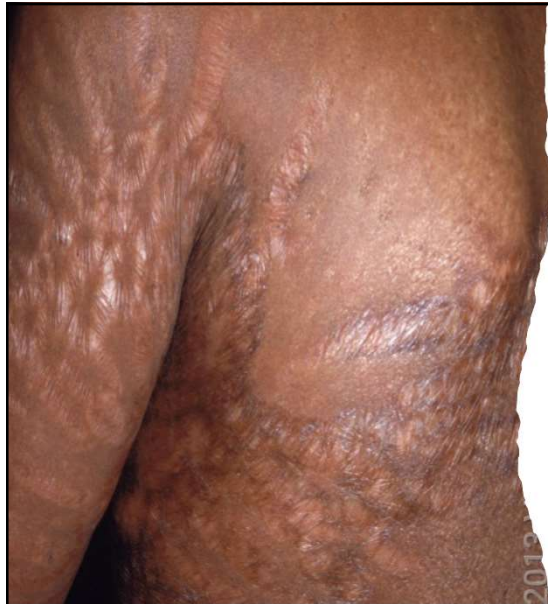

23

Topical therapies for chronic scarring skin GVHD



24



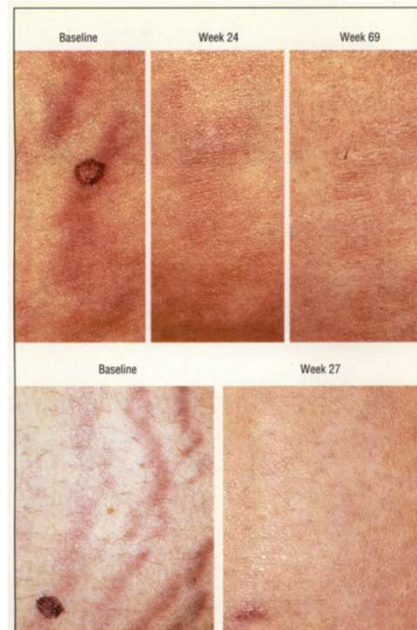Stretchmarks
may develop
with prolonged
systemic steroid
use

25

Stretchmarks: How to Treat

- Topical tretinoin improves early stretch marks
 - Reduces length and width of stretchmarks
- May experience dryness, erythema, skin peeling with treatment

Kang S. Arch Dermatol. 1996;132(5):519-526.



26

Stretchmarks may be treated with laser



Thin texture → Laser (e.g. fractional CO2 or Er:YAG laser)



Pink → Laser (e.g. pulsed dye laser)



2023 SURVIVORSHIP SYMPOSIUM

27

CO2 laser may have a positive effect on late-stage stretchmarks



Lee SE. *Dermatologic Surgery*. 2010; 36 (11): 1683-1690.

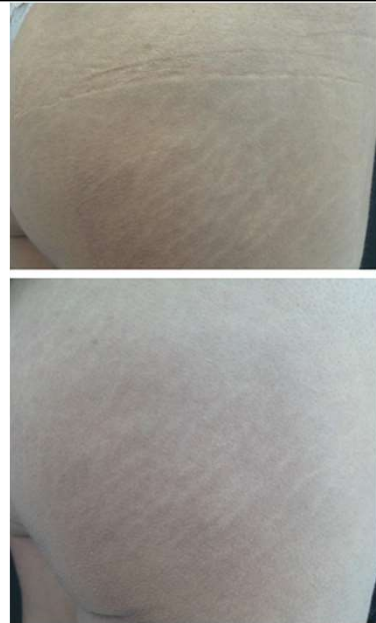

2023 SURVIVORSHIP SYMPOSIUM

28

Microneedling may be a safe and effective treatment for stretchmarks

- Striae improved by >50% after ~2 treatments
- Main side effects are transient erythema (pinkness)



29

Cleansing when you have skin GVHD

Handwashing

- Wash your hands to prevent infections
- Dry your hands with a clean towel but leave some water on your hands
- Fragrance-free moisturizer

Showers

- <20 min bath/shower with lukewarm water
- Use gentle, fragrance-free soap or cleanser (bar soaps)
- Avoid antibacterial soaps/cleansers (with triclosan)

30



Order of skin products when you have GVHD

1. +/- Medicated cream or ointment
2. Moisturizer
3. Sunscreen
4. +/- Makeup

BMT 30 YEARS EMPOWERING PATIENTS
infonet.org

2023 SURVIVORSHIP SYMPOSIUM

31

Order of skin products when you have GVHD

1 +/- Medicated cream or ointment	2 Moisturizer	3 Sunscreen	4 +/- Makeup
---	-------------------------	-----------------------	------------------------

BMT 30 YEARS EMPOWERING PATIENTS
infonet.org

2023 SURVIVORSHIP SYMPOSIUM

32

Moisturizing when you have skin GVHD

Choose Choose an ointment or cream

Apply

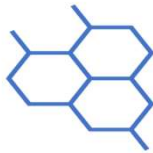Apply petroleum jelly or moisturizer you care team recommends when skin still damp

Seal

Cover moisturized hands/feet with cotton gloves or socks to seal in the moisture.

33

Choosing a sunblock when you have skin GVHD: Two categories of sunscreens



Chemical:

octinoxate, oxybenzone, avobenzone

- Easier to spread on skin
- Available in water-resistant options
- May be best if you do not have sensitive skin



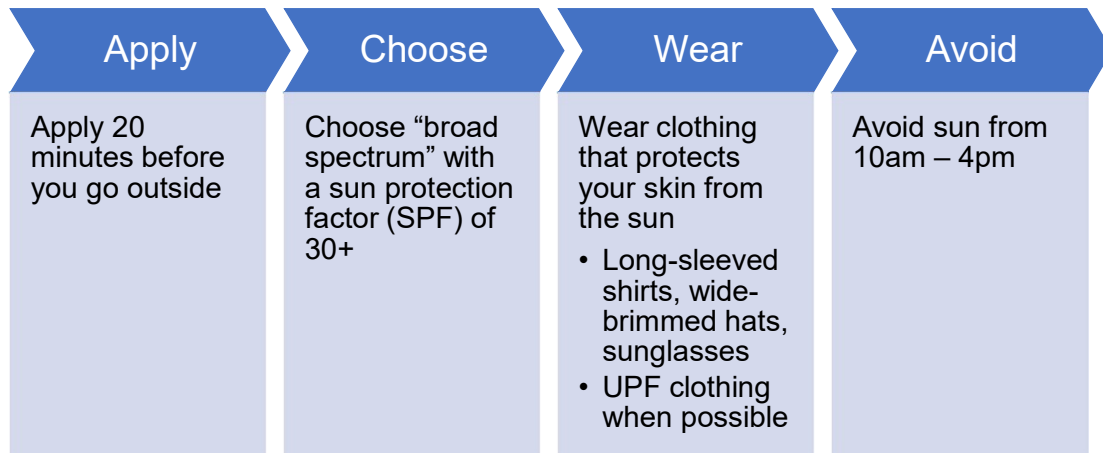
Mineral:

zinc oxide, titanium dioxide

- Thicker, may not rub into skin easily
- Better choice for sensitive skin

34

How to sunprotect when you have GVHD



35

Using makeup when you have skin GVHD



Choose fragrance-free products made for sensitive skin



Avoid products that are:

Natural or unpreserved: they have germs



Try one product at a time every few days

You may have new allergies, even to products you used previously



OK to use:

Makeup to cover a rash if the skin is not broken

Concealer to cover dark spots or light spots

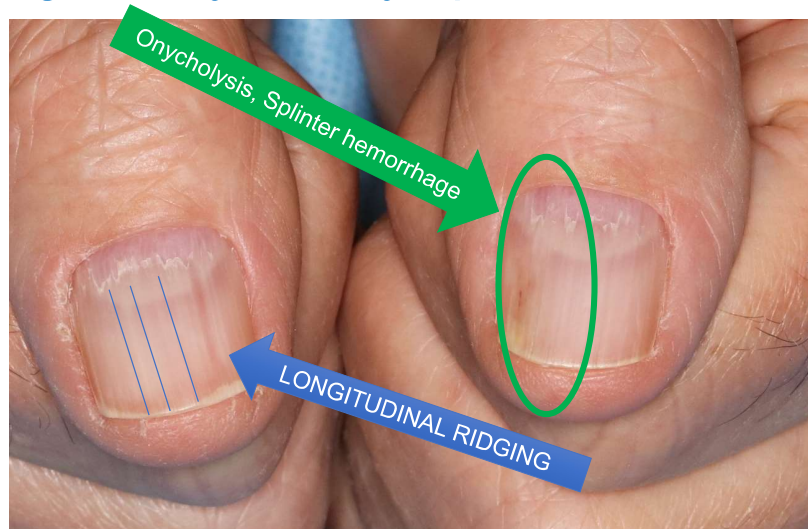
36

Replace makeup products when you have skin GVHD

- Throw out your older products and buy new ones regularly
 - Replace mascaras every few months
 - Replace eyeshadow every year
 - Replace foundation every 1-2 years
 - Replace lipsticks and blushes every 1-2 years

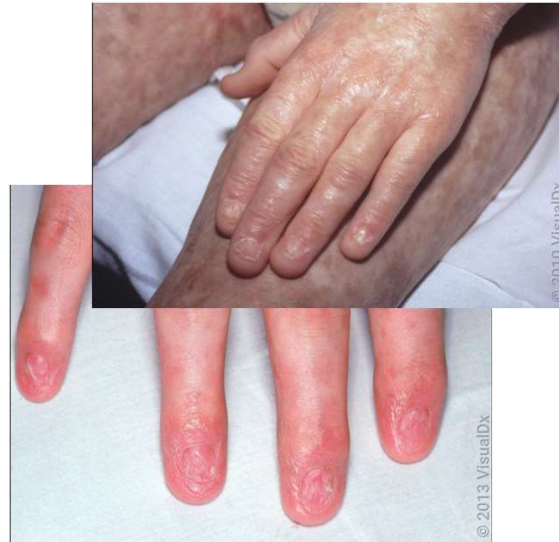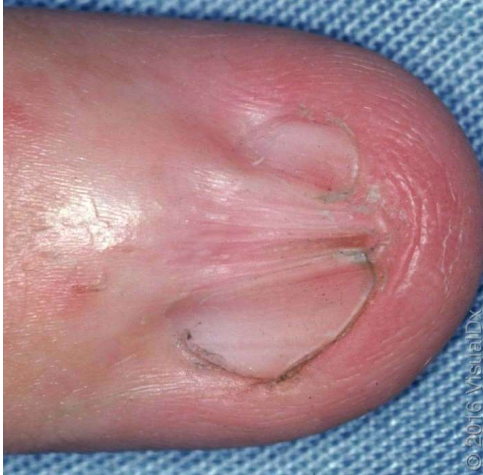37

Nail changes may be asymptomatic



38

Patients may experience loss of nail



39

GVHD of the Nails: How to Treat GVHD

Brittle, Breaking, Lifting, Scarring

- Sally Hansen Hard as Nails™
- Nailtek™
- Oral biotin
- High potency topical steroid

Scarring

- Steroid injection into nail fold
- Systemic therapy for GVHD

40

Most allogeneic transplant recipients experience hair loss (alopecia)

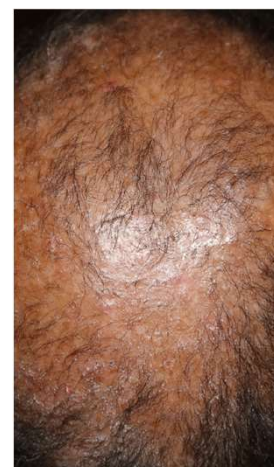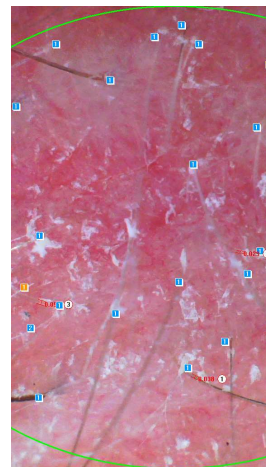
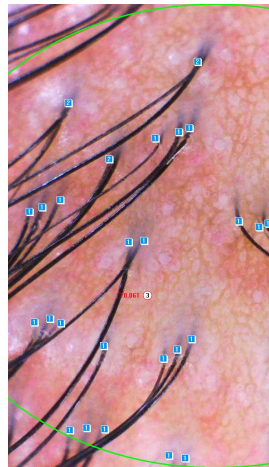
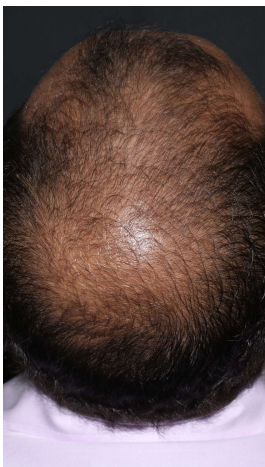Anagen effluvium = Hair loss in the first 6 months after chemotherapy

Persistent chemotherapy induced alopecia = hair loss lasting > 6 months after chemotherapy

GVHD associated hair loss may occur as part of chronic GVHD

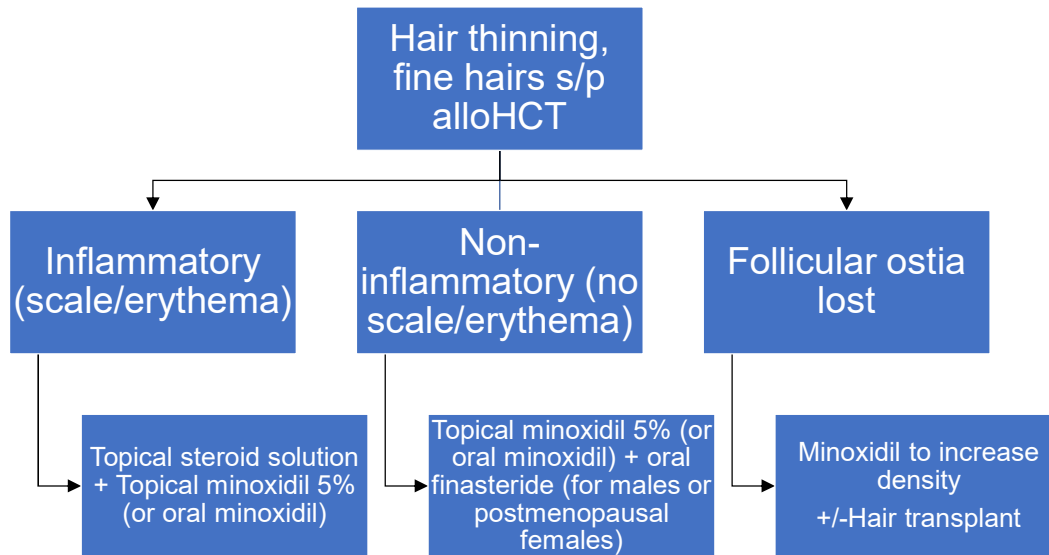
41

GVHD hair loss may be scarring or non-scarring



42

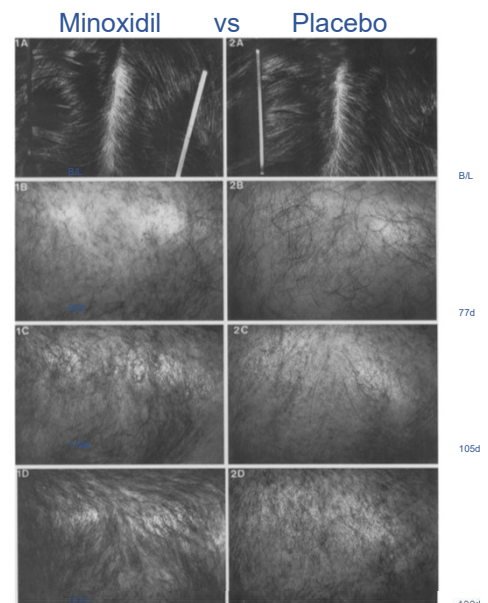
Topical therapies for GVHD of scalp/hair



43

Minoxidil shortens period of baldness

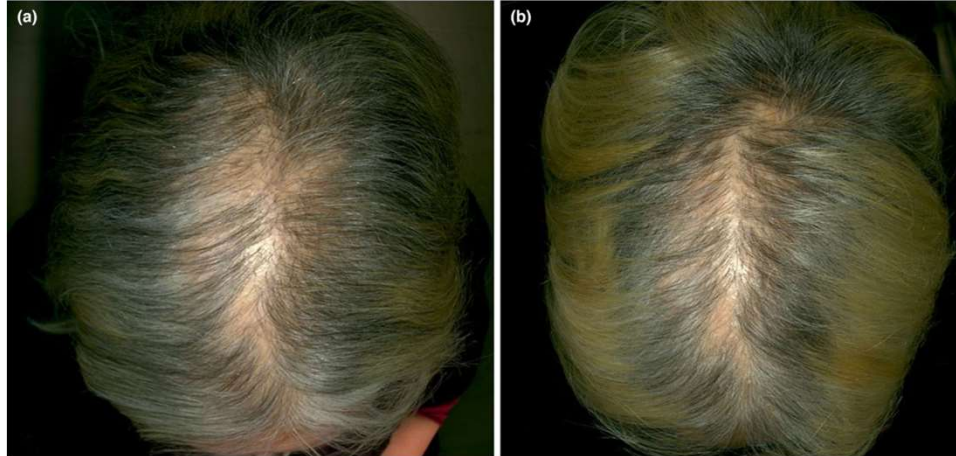
- Minoxidil shortened period of baldness by avg 50.2 days
- Does not prevent alopecia



J Am Acad Dermatol 1996;35:74-8.

44

Minoxidil may help appearance scarring GVHD by increasing background hair density



Baseline and after 12 mo of oral minoxidil in scarring hair loss

Gallo. J Eur Acad Dermatol
Venereol. 2023 Jan;37(1):

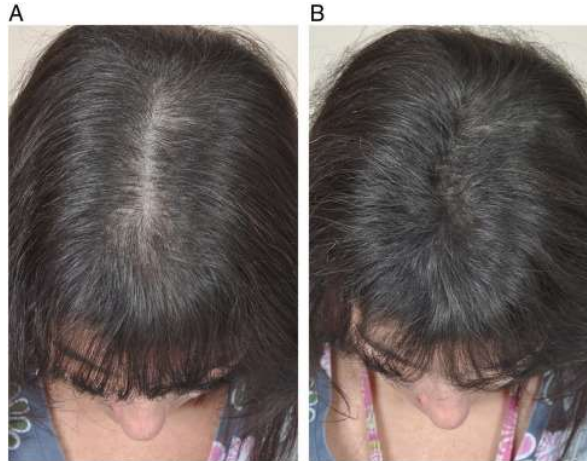2023 SURVIVORSHIP SYMPOSIUM

Hair care when you have GVHD of the scalp

- Wash and condition your hair every 2 – 4 days
- Use a shampoo and a cream rinse or hair conditioner
- When you brush or comb your hair, start at the ends. Use a soft-bristle brush, a comb, or your fingers.
- Use OTC antifungal shampoo or prescription ketoconazole shampoo for dandruff / scale

Pigmented concealing powders can camouflage hair thinning

- Powders
- Lotions
- Sprays

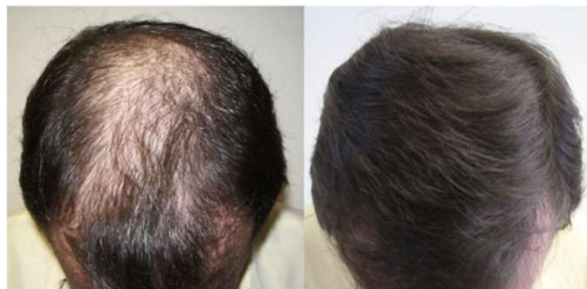

47

Hair transplantation may be used once GVHD is inactive

Advantages

- Effective and permanent
- Performed under local anesthesia

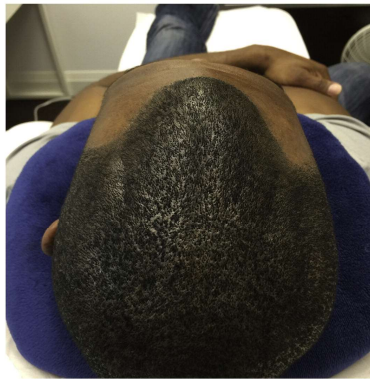
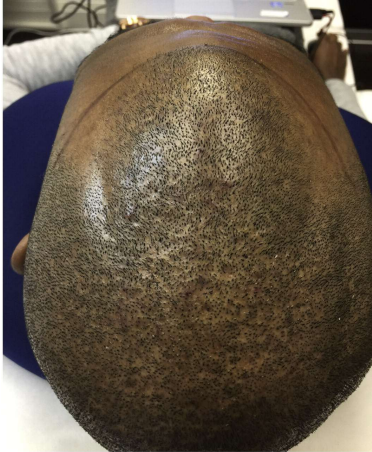
Disadvantages

- Risk of scalp swelling, bleeding, minor infections
- Risk of unnatural looking hair
- Creation of donor site scar
- Expensive

48

Micropigmentation recreates appearance of hair follicles



Advantages

- Relatively permanent
- Resembles pores on a scalp

Disadvantages

- Risk of infection from procedure
- Risk of allergy to pigment
- Natural hair must be dyed to match pigment
- May need touchups over time

GVHD of the skin, hair, and nails: SUMMARY

- Acute GVHD of the skin presents as a maculopapular rash
- Chronic GVHD may affect the skin, hair, or nails
- Many treatments are available that improve quality of life
- Notify your care team if you develop signs of symptoms of skin, hair, or nail GVHD
- **TIP: In the age of telehealth, always document any new rashes with photos!**

